Enfermedades Infecciosas y Microbiología Clínica xxx xxxx xxx–xxx

Enfermedades Infecciosas y Microbiología Clínica
www.elsevier.es/eimc

Scientific letter

Multisystem inflammatory syndrome in adults associated to SARS-CoV-2☆,☆☆

Síndrome inflamatorio multisistémico del adulto asociado a SARS-CoV-2

Paediatric multisystem inflammatory syndrome is a condition described in 2020 as a result of the COVID-19 pandemic and whose pathogenesis is not completely clear.[1] Cases have also been described in adults, in whom it is much more infrequent; the largest series published to date is of 51 cases.[2]

We describe a case of multisystem inflammatory syndrome in adults (MIS-A) and its histopathology.

The patient was a 31-year-old woman, with a history of lymphocytic meningitis of probable viral origin in 2010 and pyelonephritis in 2018. She was diagnosed in January 2021 with mild COVID-19 (positive antigen test), progressed favourably and was discharged two weeks later. Four weeks later she began with fever, headache, vomiting, mild diarrhoea and very intense pain in the right iliac fossa (RIF) for which she went to the emergency department. She was admitted on the fourth day after the onset of symptoms. At that time, she was febrile (38.5 °C), with blood pressure of 95/70 mmHg, heart rate of 96 bpm and baseline oxygen saturation of 98%. Of note were her mucocutaneous pallor, RIF pain on palpation and mild neck stiffness. Laboratory tests revealed thrombocytopenia, anaemia, lymphopenia, and elevated ESR, D-dimer, ferritin and C-reactive protein (Appendix B). An ECG showed sinus tachycardia. An urgent abdominal CT revealed mesenteric adenopathy. A SARS-CoV-2 PCR test (GeneXpert®, Cepheid) of nasopharyngeal swab was positive with a cycle threshold (Ct) >30. Lumbar puncture was normal. Blood cultures, stool cultures and urine cultures were negative. Serologies, performed with chemiluminescence immunoassay, were negative for HIV (IgM + IgG + agp24), syphilis (IgG + IgM), *Toxoplasma*, mumps, rubella, *Coxiella*, *Rickettsia*, *Bartonella* and *Legionella* (IgG and IgM), hepatitis C (IgG) and hepatitis B (negative HBsAg, anti-HBs and anti-HBc), while positive IgG was detected with negative IgM for CMV, EBV, parvovirus and VZV and positive IgG for SARS-CoV-2. A PCR test for *Leishmania* (Werfen) was negative. The autoimmunity study was normal.

The patient's condition deteriorated on the ward, with worsening clinical signs and test results (Appendix B), so treatment with piperacillin-tazobactam and doxycycline was started. On the fourth day after admission, she presented shock (BP: 70/40 mmHg; HR: 136 bpm) and severe oliguria, which did not respond to fluid therapy, so a new thoraco-abdominopelvic CT (Appendix B) was performed, which showed generalised adenopathy, especially in the root of the mesentery and RIF, mild splenomegaly, fluid in the pericardial recess, periportal oedema and mild to moderate ascites. She was admitted to the ICU and treated with piperacillin-tazobactam, linezolid, ganciclovir and liposomal amphotericin B, pending microbiological results. Suspecting septic shock of abdominal/gynaecological origin, an exploratory laparotomy was performed, which resulted in no pathological findings, except for mesenteric and mesocolic lymphadenitis. The affected lymph nodes were resected.

The biopsy revealed necrotising lymphadenitis and reactive lymphoid hyperplasia with extensive sinusoidal histiocytosis, with no haemophagocytosis phenomena observed (Fig. 1). A PCR test for SARS-CoV-2 in the lymph node (GeneXpert®, Cepheid) was positive. The patient was started on dexamethasone (20 mg/day), with clinical improvement; the norepinephrine was withdrawn and she was sent back to the ward. There, her vomiting and cytopenia persisted and she required the transfusion of two units of packed red blood cells due to anaemia. A bone marrow biopsy (Appendix B) showed moderate hypocellularity, with a mosaic pattern. An echocardiogram showed mild pericardial effusion and normal systolic and coronary function. Lastly, MIS-A was diagnosed, since it met the criteria for a definitive case.[3] Intravenous immunoglobulin (IVIG) (2 g/kg) was added, with improved clinical signs and test results being observed. The patient was discharged with decreasing corticosteroids, acetylsalicylic acid (100 mg/day) and prophylactic enoxaparin. Six weeks later, she was asymptomatic and an echocardiogram was normal, so the acetylsalicylic acid was withdrawn.

The patient was initially managed as a case of haemophagocytic lymphohistiocytosis.[4] However, she met criteria for a definitive case (level 1) of MIS-A, according to the *Brighton Collaboration* case definitions of 2021,[3] and her response was very good to treatment with IVIG and corticosteroids. The pathogenesis of MIS-A is unknown. It could be due to an aberrant interferon response that leads to a hyperinflammatory state, with endothelial dysfunction and microangiopathy.[1] Most of the cases described are in young adults from ethnic minorities[5,6] two to five weeks after SARS-CoV-2 infection, with predominantly cardiac and gastrointestinal involvement and a mortality rate of 3.9–11.1%.[2,5,6] Cases associated with vaccination against SARS-CoV-2 have also been described.[7] Treatment is extrapolated from paediatric recommendations[8]; the use of IVIG and corticosteroids[9] is recommended, although a recent article has found no benefit from the combination in children.[10]

In conclusion, MIS-A should be suspected in all adults with a history of COVID-19 in the last 12 weeks who present with fever, inflammatory markers, cardiovascular involvement and extrapulmonary organ involvement, and early treatment with IVIG or corticosteroids should be established.

DOI of original article: https://doi.org/10.1016/j.eimc.2021.10.009

☆ This case was awarded first prize in the COVID SEIMC-Gilead clinical case contest at the XXIV Congress of the Sociedad Española de Enfermedades Infecciosas y Microbiología Clínica, held online from 5 to 11 June 2021.

☆☆ Please cite this article as: Llenas-García J, Paredes-Martínez ML, Boils-Arroyo PL, Pérez-Gómez IM. Síndrome inflamatorio multisistémico del adulto asociado a SARS-CoV-2. Enferm Infecc Microbiol Clin. 2022. https://doi.org/10.1016/j.eimc.2021.10.009

2529-993X/© 2022 Published by Elsevier España, S.L.U. on behalf of Sociedad Española de Enfermedades Infecciosas y Microbiología Clínica.

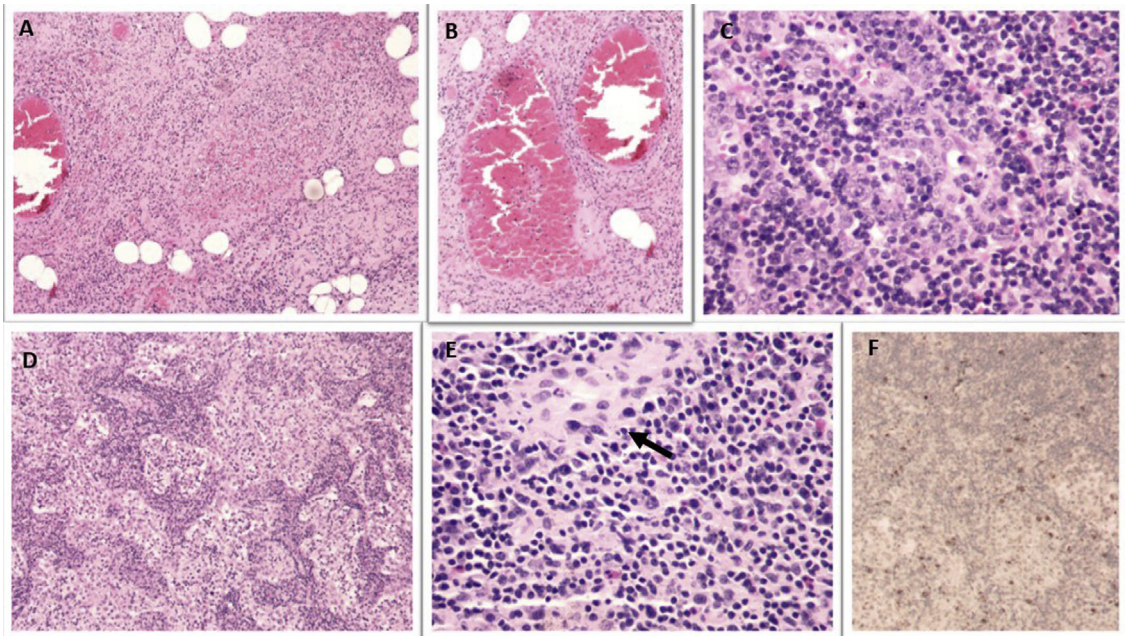

Fig. 1. Lymph nodes with necrotising lymphadenitis: ischaemic necrosis with necrotising vasculitis (**A**), periganglionic vessels with red thrombus (**B**), follicular hyperplasia with immunoblastic reaction (**C**), plasmacytosis and sinus histiocytosis (**D**). Presence of occasional microgranulomas (**E**) *(arrow)*. Positive immunohistochemistry for SARS-CoV-2 (**F**).

Funding

We confirm that no funding was received from any organisation or institution for the writing of this manuscript.

Conflicts of interest

The authors declare that they have no conflicts of interest.

Appendix A. Supplementary data

Supplementary material related to this article can be found, in the online version, at doi:https://doi.org/10.1016/j.eimc.2021.10.009.

References

1. Kabeerdoss J, Pilania RK, Karkhele R, Kumar TS, Danda D, Singh S. Severe COVID-19, multisystem inflammatory syndrome in children, and Kawasaki disease: immunological mechanisms, clinical manifestations and management. Rheumatol Int. 2021;41:19–32. Available from: https://pubmed.ncbi.nlm.nih.gov/33219837/. [cited 2021 April 17].
2. Bastug A, Aslaner H, Aybar Bilir Y, Kemirtlek N, Gursoy FM, Bastug S, et al. Multiple system inflammatory syndrome associated with SARS-CoV-2 infection in an adult and an adolescent. Rheumatol Int. 2021;41. Available from: https://pubmed.ncbi.nlm.nih.gov/33742229/. [cited 2021 April 17].
3. Vogel TP, Top KA, Karatzios C, Hilmers DC, Tapia LI, Moceri P, et al. Multisystem inflammatory syndrome in children and adults (MIS-C/A): case definition & guidelines for data collection, analysis, and presentation of immunization safety data. Vaccine. 2021.
4. La Rosée P, Horne AC, Hines M, Greenwood TVB, Machowicz R, Berliner N, et al. Recommendations for the management of hemophagocytic lymphohistiocytosis in adults. Blood. 2019;133:2465–77. Available from: http://ashpublications.org/blood/article-pdf/133/23/2465/1553600/blood894618.pdf. [cited 2021 April 17].
5. Morris SB, Schwartz NG, Patel P, Abbo L, Beauchamps L, Balan S, et al. Case series of multisystem inflammatory syndrome in adults associated with SARS-CoV-2 infection — United Kingdom and United States, March–August 2020. MMWR Morb Mortal Wkly Rep. 2020;69:1450–6. Available from: https://pubmed.ncbi.nlm.nih.gov/33031361/. [cited 2021 April 17].
6. Davogustto GE, Clark DE, Hardison E, Yanis AH, Lowery BD, Halasa NB, et al. Characteristics associated with multisystem inflammatory syndrome among adults with SARS-CoV-2 infection. JAMA Network Open. 2021;4. Available from: https://pubmed.ncbi.nlm.nih.gov/34009351/. [cited 2021 July 10].
7. Salzman MB, Huang C-W, O'Brien CM, Castillo RD. Multisystem inflammatory syndrome after SARS-CoV-2 infection and COVID-19 vaccination. Emerg Infect Dis. 2021;27:1944–8. Available from: https://pubmed.ncbi.nlm.nih.gov/34034858/. [cited 2021 July 10].
8. García Salido A, Antón J, Marínez-Pajares JD, Giralt García G, Gómez-Cortés B, Tagarro A. Grupo de trabajo de la Asociación Española de Pediatría para el síndrome inflamatorio multisistémico pediátrico vinculado a SARS-CoV-2, Consenso nacional sobre diagnóstico, estabilización y tratamiento del síndrome inflamatorio multisistémico pediátrico vinculado a SARS-CoV-2. (SIM-PedS). Anales Pediat. 2021;94, 116.e1–11.
9. Son MBF, Murray N, Friedman K, Young CC, Newhams MM, Feldstein LR, et al. Multisystem inflammatory syndrome in children — initial therapy and outcomes. N Engl J Med. 2021;385:23–34. Available from: https://www.nejm.org/doi/full/10.1056/NEJMoa2102605. [cited 2021 July 10].
10. McArdle AJ, Vito O, Patel H, Seaby EG, Shah P, Wilson C, et al. Treatment of multisystem inflammatory syndrome in children. N Engl J Med. 2021;385:11–22. Available from: https://pubmed.ncbi.nlm.nih.gov/34133854/. [cited 2021 July 10].

Jara Llenas-García[a,b,*], Mari Luz Paredes-Martínez[c], Pedro Luis Boils-Arroyo[d], Isabel María Pérez-Gómez[e]

[a] *Servicio de Medicina Interna-Infecciosas, Hospital Vega Baja, FISABIO, Orihuela (Alicante), Spain*
[b] *Departamento de Medicina Clínica, Universidad Miguel Hernández, Elche (Alicante), Spain*
[c] *Servicio de Radiodiagnóstico, Hospital Vega Baja, FISABIO, Orihuela (Alicante), Spain*
[d] *Servicio de Anatomía Patológica, Hospital Vega Baja, FISABIO, Orihuela (Alicante), Spain*
[e] *Unidad de Medicina Intensiva, Hospital Vega Baja, FISABIO, Orihuela (Alicante), Spain*

* Corresponding author.
E-mail address: jarallenas@gmail.com (J. Llenas-García).